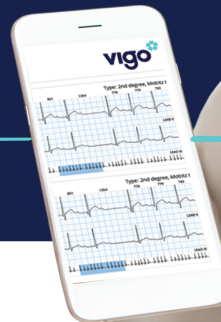



SmartHeart

# CAPTURE THE RHYTHM OF THE HEART

Clinically accurate and easy arrhythmia  
detection through continuous ECG monitoring.  
Anytime | Anywhere



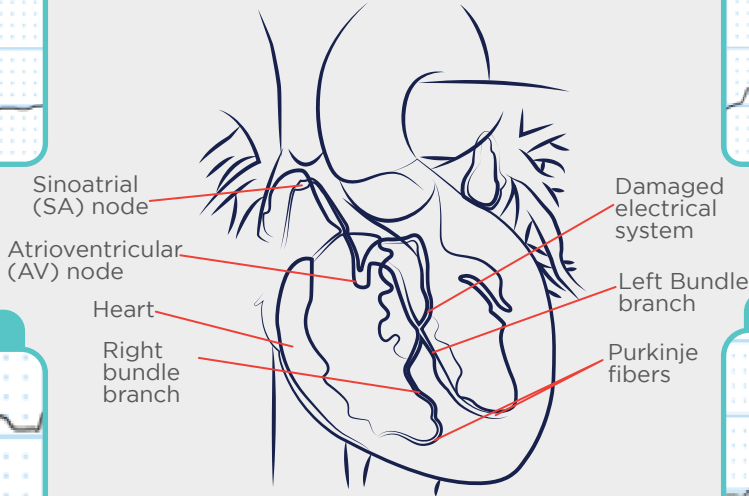
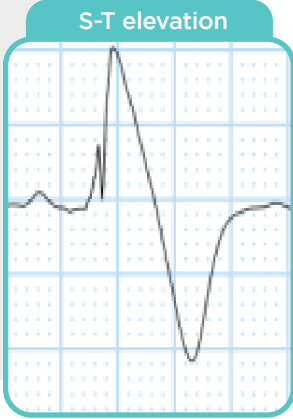
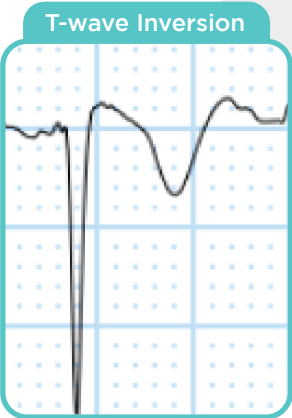
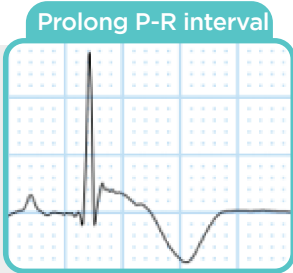
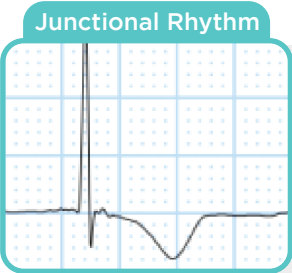


# VIGO ECG CASE ANALYSIS COLLECTION

1. Brugada Syndrome Unmasked By Pneumonia .....	04
2. Pneumonia As A Trigger For Atrial Fibrillation .....	06
3. Wolff-parkinson-white Syndrome Long-term Monitoring For Arrhythmias .....	08
4. Long Qt Syndrome .....	10
5. De Winter Pattern .....	12
6. Sino Atrial Exit Block .....	14
7. High Grade AV Block .....	16
8. Tachy-brady Syndrome .....	18
9. Multifocal Atrial Tachycardia .....	20
10. Atrial Flutter .....	22
11. Non-sustained Ventricular Tachycardia .....	24
12. Supraventricular Tachycardia .....	25
13. report Features .....	26
14. How It Works .....	27



# BRUGADA SYNDROME UNMASKED BY PNEUMONIA



**Damaged electrical system of heart**



# CASE ANALYSIS 01

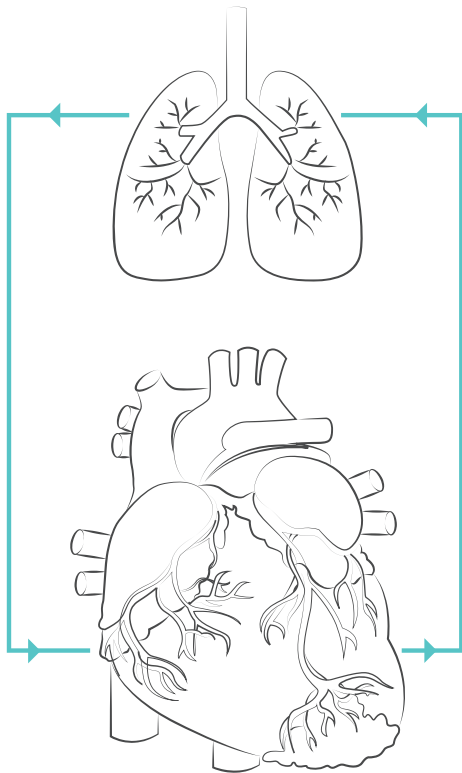
## BRUGADA SYNDROME UNMASKED BY PNEUMONIA

A 54-year-old hypertensive male patient was diagnosed with H/O left lung pneumonia, fever, and chest pain. Incidentally, the patient had lost his brother to an unexplained and sudden death. The doctor recommended continuous observation with the help of **Vigo Multi-Vital Remote Home Monitoring**. The ECG changes indicated **Type-1 Brugada Pattern**, which was diagnosable only through continuous observation. The family history helped with the co-relation of the findings. With the EP's timely intervention, the patient underwent surgery for the placement of an Implantable Cardioverter-Defibrillator.

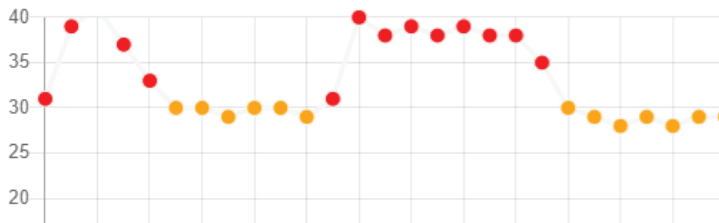
**Timely diagnosis and treatment saved his life.**



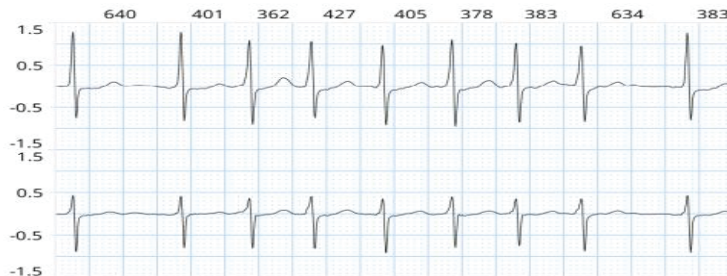# PNEUMONIA AS A TRIGGER FOR ATRIAL FIBRILLATION



## Elevated Respiratory Rate



## Atrial Fibrillation



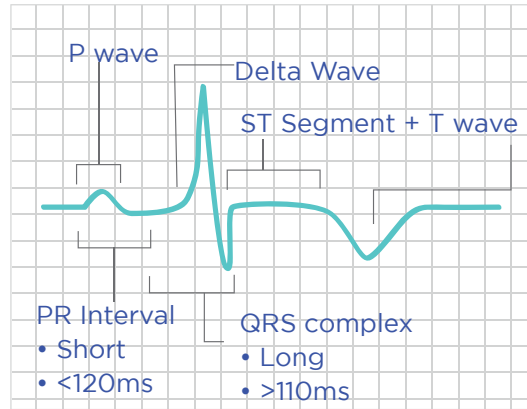
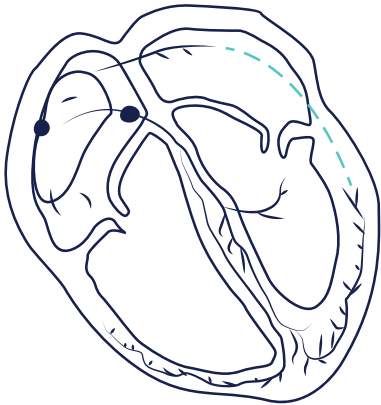
## CASE ANALYSIS 02

### PNEUMONIA AS A TRIGGER FOR ATRIAL FIBRILLATION

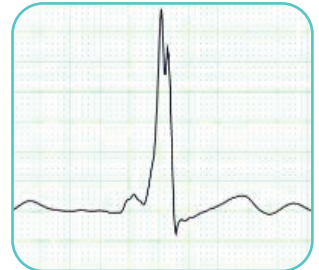
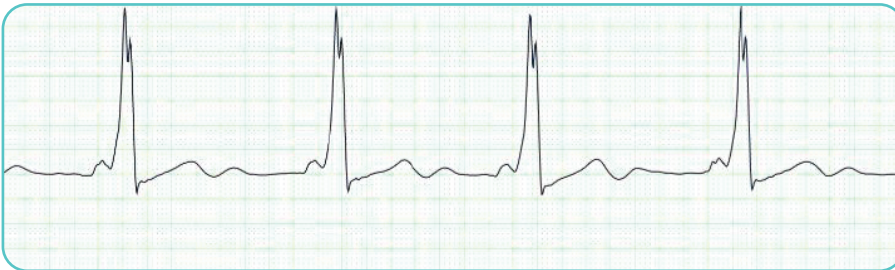
A 70-year-old hypertensive and diabetic male presented H/O chest congestion, breathing difficulty, and chest pain symptoms. Due to his COVID-19 history and prior hospitalization, he preferred home isolation. With the help of Vigo Multi-Vital Monitoring, he presented a continuous rise in RR and ECG, indicating Atrial Fibrillation on day 3. The patient was immediately shifted to the ICU to manage both cardiac and pulmonary conditions. Heparin was administered with electrical cardioversion. Vigo Monitoring enabled continuous contact with the doctor, which lead to timely detection and intervention.



# WOLFF-PARKINSON-WHITE SYNDROME LONG-TERM MONITORING FOR ARRHYTHMIAS



Delta Wave | Prolonged QRS complex | Short PR Interval



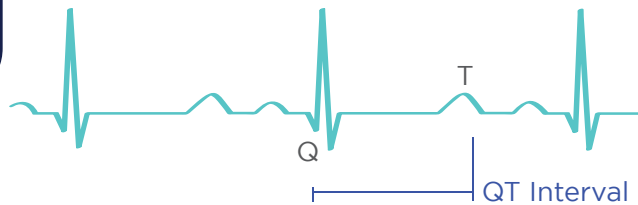
CASE ANALYSIS **03****WOLFF-PARKINSON-WHITE SYNDROME  
LONG-TERM MONITORING FOR ARRHYTHMIAS**

A 28-year-old female patient complained of giddiness and palpitations and the doctor advised long-term ECG monitoring. Evaluation revealed Wolff-Parkinson-White (WPW) Syndrome with tachyarrhythmia. This diagnosis is difficult because episodes of tachyarrhythmia often subside spontaneously before medical observation. It can be **diagnosed with a system that allows the flexibility of activity** during the monitoring period. **Vigo SmartHeart**, a wireless solution, gave the patient this flexibility. After the diagnosis, she received **Propranolol Hydrochloride Therapy**, which improved her condition and **averted a catastrophe**. Follow-up ECG monitoring confirmed the clinical impression of improvement.

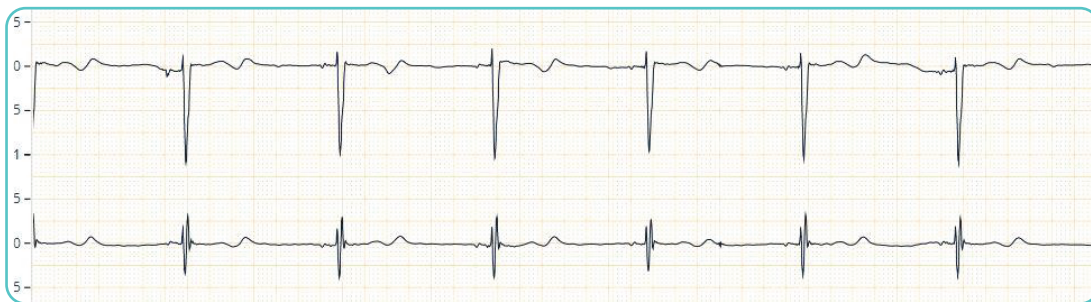**The right device at the right time can save lives.**



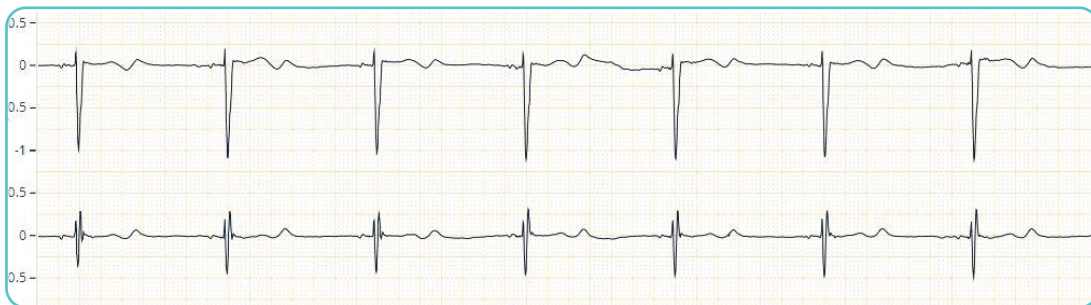# LONG QT SYNDROME



QT (Interval 532ms)



QT (Interval 560ms)



## CASE ANALYSIS 04

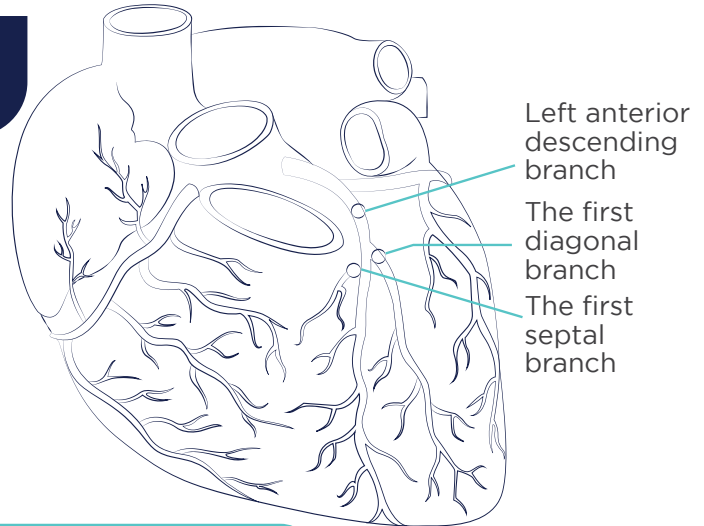
### LONG QT SYNDROME

A 56-year-old woman presented diarrhea and fever for 4 days. She was confirmed to have COVID-19 related pneumonia. She denied having any chronic illness and was not taking related medication. The patient was advised to choose Vigo Multi-Vital Monitoring for recovery. Her treatment included oral anti-viral Lopinavir/ritonavir (400/100 mg), Pantoprazole (40 mg), Methylprednisolone (20 mg), Chloroquine (0.25 g) for 10 days. On day 10, her atrial rate was recorded to be 39 BPM and her calculated QTc was 560 ms. There was a complete AV block of 2656 ms and junctional rhythm. The doctor advised immediate admission and Lopinavir withdrawal with attention to her AV block. Her QTc subsequently decreased to 410 ms.

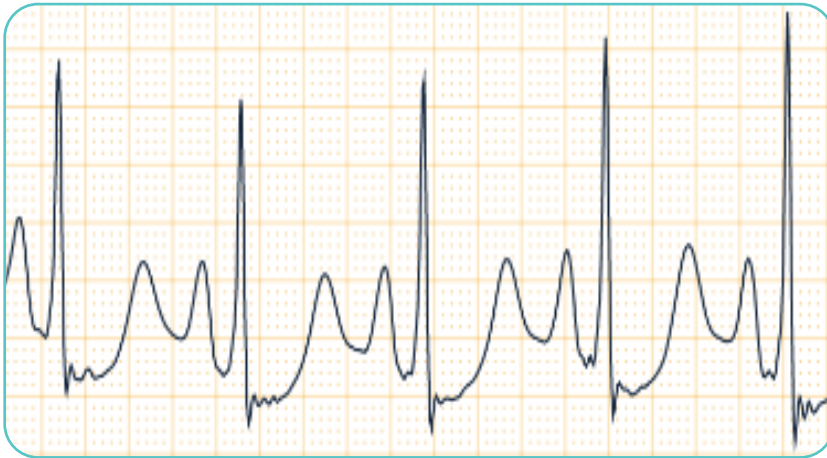
**Vigo Multi-Vital played a significant role in early diagnosis and intervention.**



## DE WINTER PATTERN



ST segment presents upward oblique depression with T wave upright





## CASE ANALYSIS 05

### DE WINTER PATTERN

A 55-year-old patient complained of chest pain for 20 minutes. He was a smoker but without previous cardiovascular diseases. The ECG showed DWP and urgent coronary angiography was performed. It showed the occlusion of the proximal left anterior descending coronary artery. Despite prompt and successful revascularization with primary percutaneous coronary intervention, the patient developed acute pulmonary oedema. Invasive ventilation was started and the circulation was supported by an intra-aortic balloon pump as well as dobutamine and norepinephrine infusions. On day 17, he was discharged in good general health condition despite the dramatic acute decompensation.

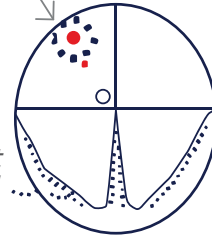
**Timely diagnosis with Vigo ECG monitoring and immediate treatment saved his life.**



# SINO ATRIAL EXIT BLOCK

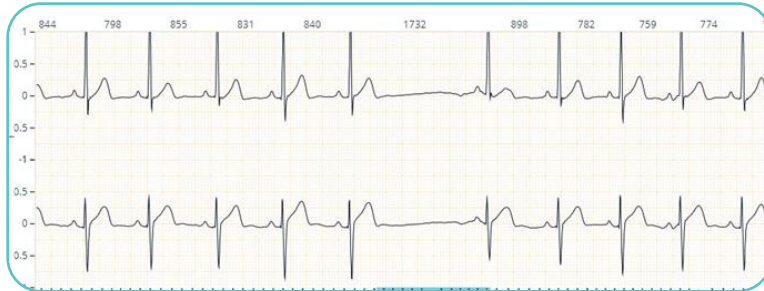
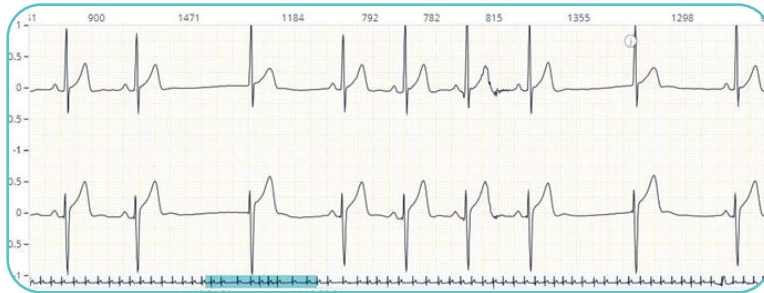
*Sinus Impulse cannot always get past surrounding tissue*



*One beat dropped ...*

*Next beat falls into sequence*



## CASE ANALYSIS 06

### SINO ATRIAL EXIT BLOCK

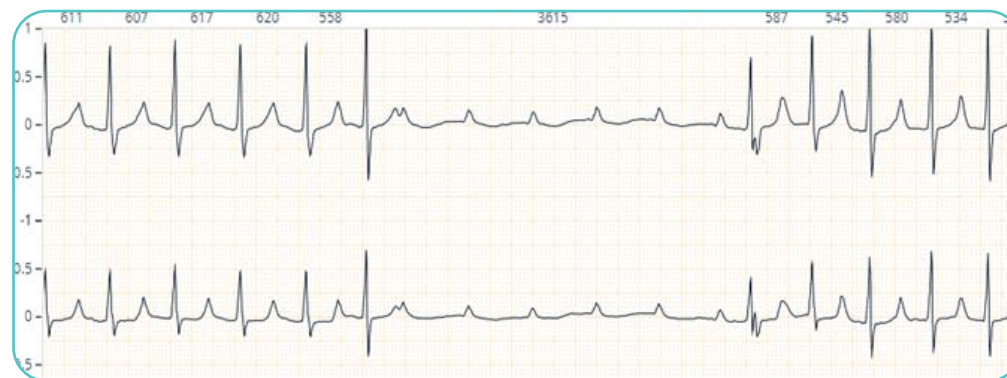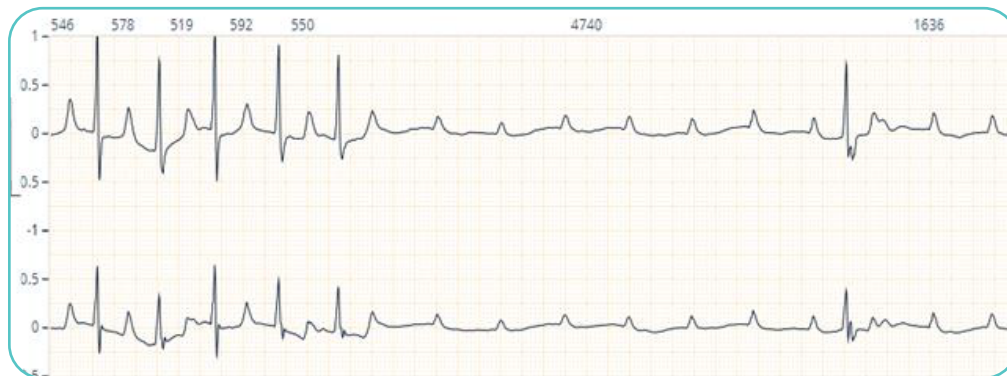A 35-year-old male patient with a medical history of hypertension, asthma, and hyperlipidemia was presented to the emergency department with a chief complaint of syncope preceded by headache. Physical examination did not reveal any focal neurological deficits. His vitals at that time showed:

**Blood pressure: 141/82 mmHg, Heart rate: 48 BPM, Respiratory rate: 19 BPM, Short ECG: Sinus rhythm and pauses with junctional escape beats and atrial premature contractions.** Laboratory investigations were within normal limits.

The case was referred to Cardiology for the management of sinus bradycardia, sinoatrial block, and junctional escape. Long-term ECG monitoring with SmartHeart indicated SA exit block. The doctor advised frequent follow-ups to check the symptoms. He was admitted for 2 days and operated with a transvenous pacemaker. Vigo SmartHeart accurately determined the cause of the problem and facilitated immediate intervention.



# HIGH GRADE AV BLOCK



## CASE ANALYSIS 07

### HIGH GRADE AV BLOCK

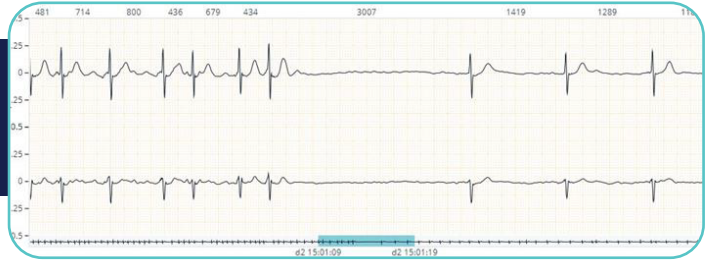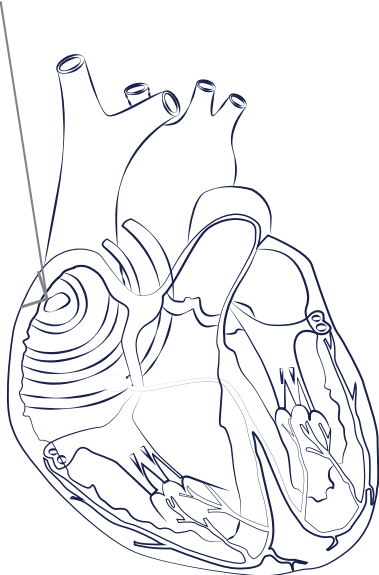
A 27-year-old female patient presented Syncope, shortness of breath, and nausea, preceded by headache. She had a surgical history of tricuspid and mitral valve replacement. In the OP, her vitals showed: Blood pressure: 100/82 mmHg, Heart rate: 48 BPM, Respiratory rate: 19 BPM, Short ECG: Bradycardia. Laboratory investigations were within normal limits. The case was referred to cardiology for the management of sinus bradycardia. SmartHeart long-term ECG monitoring revealed an advanced high grade AV block with a ventricular rate of 35 BPM. She was admitted immediately for the implantation of a permanent pacemaker.

**SmartHeart helped with accurate diagnosis and timely life-saving treatment.**

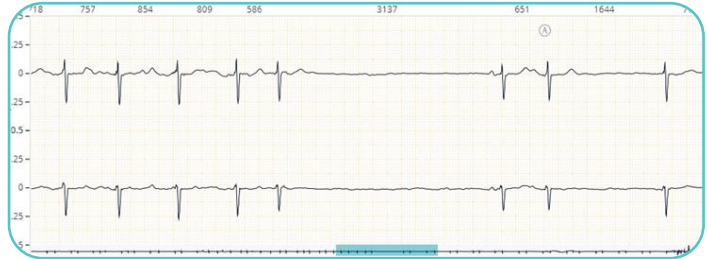

# TACHY-BRADY SYNDROME

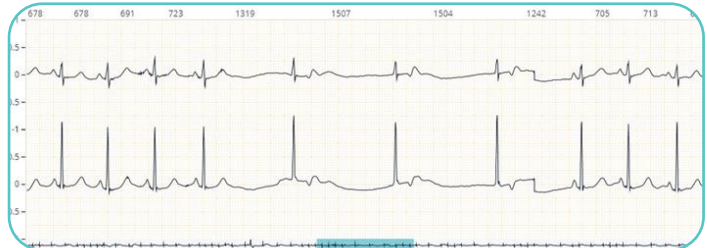*Sinus node*



*Atrial Tachycardia (Atrial Fibrillation) followed by a Prominent Sinus Pause, Junctional Bradycardia*



*Atrial Tachycardia (Atrial Fibrillation) Followed by Prominent Sinus Pause, two Sinus Beats, Junctional Escape Beat.*



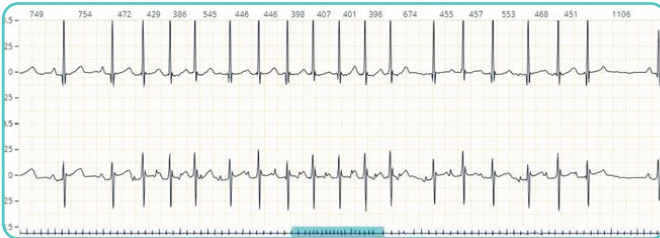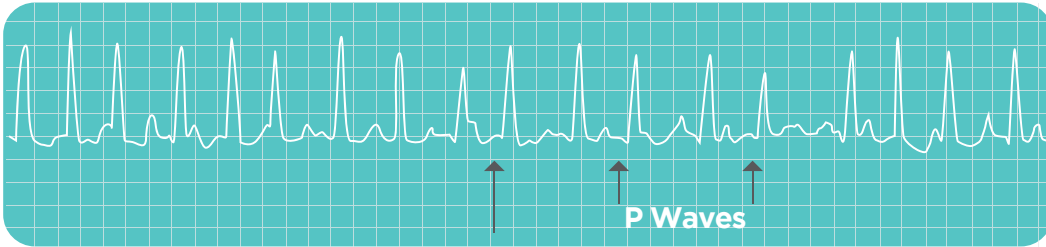## CASE ANALYSIS 08

### TACHY-BRADY SYNDROME

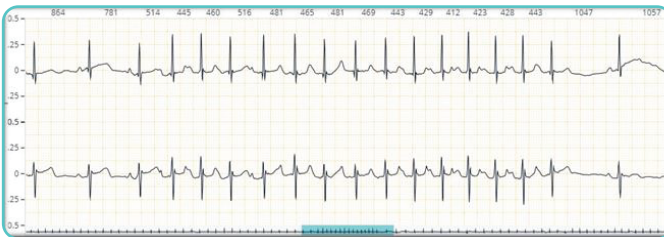A 59-year-old female patient consulted a neurologist with a chief complaint of syncope, shortness of breath, and nausea, preceded by headache. She is a known case of hypertension and diabetes. On examination, her vitals showed: Blood pressure: 100/82 mmHg, Heart rate: 48 BPM, Respiratory rate: 19 BPM, ECG: Sinus rhythm and pauses with junctional escape beats and atrial premature contractions. The case was referred to cardiology for the management of sinus bradycardia and junctional escape beats. Through continuous ECG monitoring with SmartHeart, the patient was found to have Tachy-Brady Syndrome (atrial fibrillation followed by a prominent pause with junctional bradycardia with the longest pause being 3.2 seconds). The patient was immediately admitted for permanent pacemaker implantation. **SmartHeart enabled seamless monitoring and accurate reporting, which saved her life.**



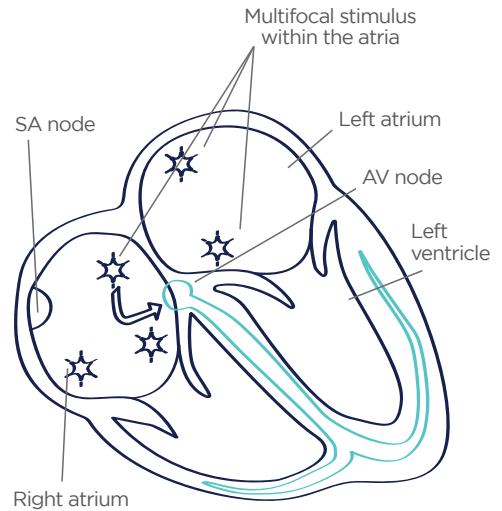
# MULTIFOCAL ATRIAL TACHYCARDIA



Different Morphology of P waves with a heart rate of 130 bpm.



Different Morphology of P waves with a heart rate of 131 bpm.





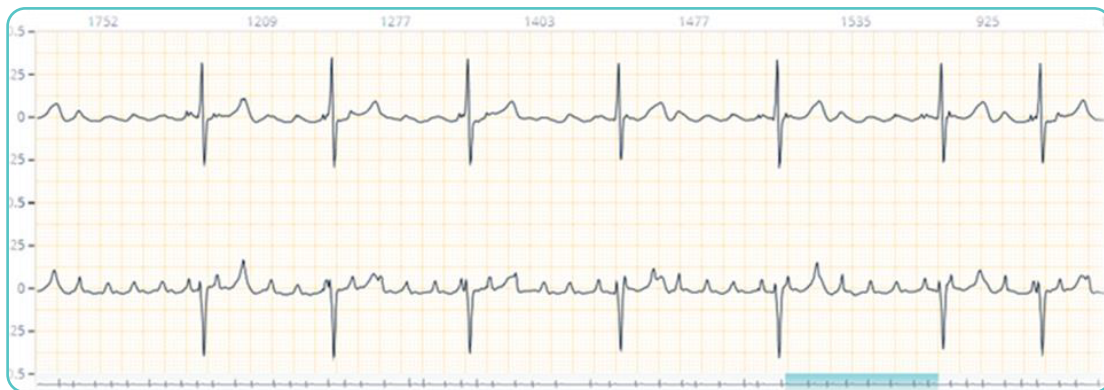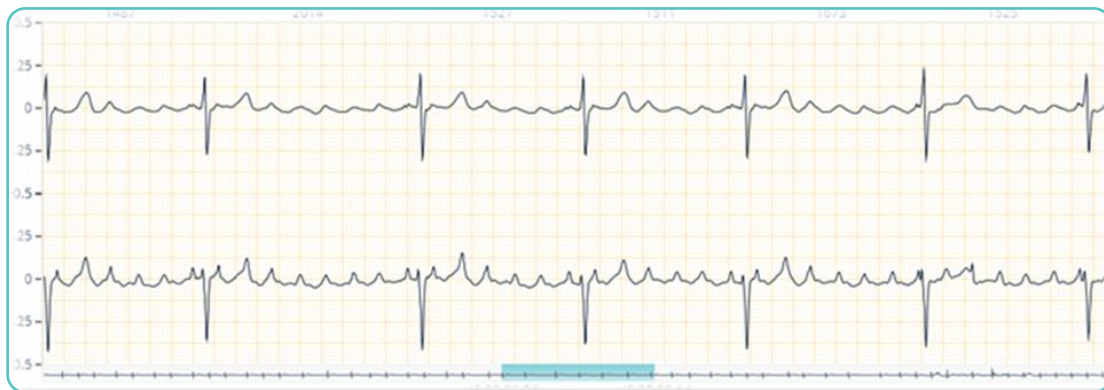CASE ANALYSIS **09****MULTIFOCAL ATRIAL TACHYCARDIA**

An 81-year-old male with a history of hypertension and diabetes for 15 years was treated recently with IV aminophylline for COPD. He visited the OP with chief complaints of syncope, palpitations, and shortness of breath. Laboratory investigations were within normal limits. His 12-lead ECG showed sinus tachycardia. To evaluate further, he was advised to go for long-term ECG monitoring with Vigo SmartHeart. ECG analysis showed a typical pattern of different P-wave morphologies with a heart rate of 130 BPM, which lead to the diagnosis of Multifocal Atrial Tachycardia. With timely medical management, sinus rhythm was presented with 6 months of follow-up.

**Medical attention at the right time can save lives.**



# ATRIAL FLUTTER



## CASE ANALYSIS 10

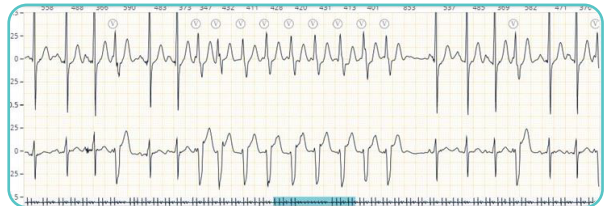
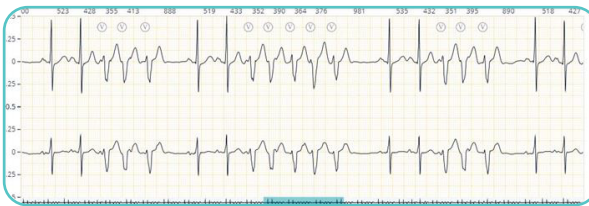
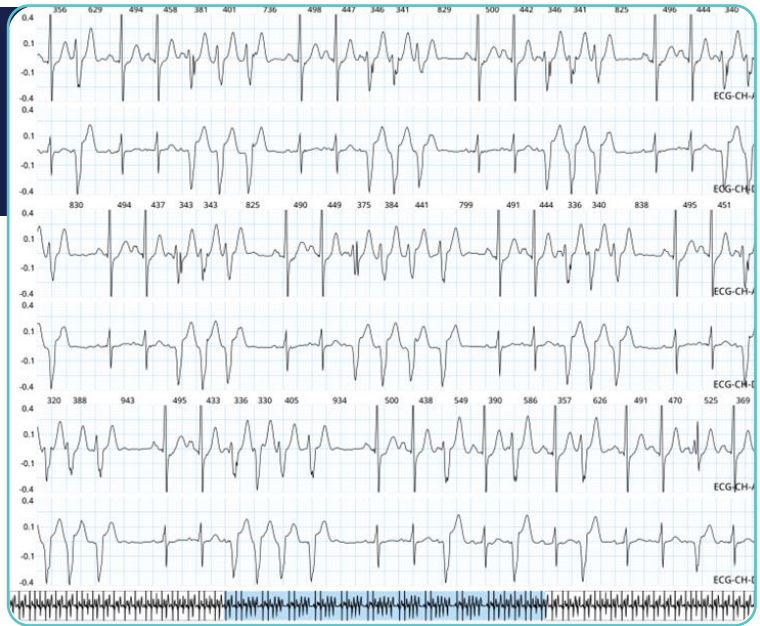### ATRIAL FLUTTER

A 70-year-old patient was presented at the OP with rectal bleeding and palpitations. He was diagnosed with hemorrhoids and needed surgical intervention. To evaluate the presenting complaints of palpitations, ECG was done. It showed irregular beats with a change in the P-wave morphology. The patient was then advised to go for long-term ECG monitoring. He was put on Vigo ECG for 24-hour monitoring. The report showed a saw-tooth appearance consistent with typical atrial flutter and ventricular conduction. The peak ventricular rate recorded was 157 BPM. The case was then first managed with anti-arrhythmic drugs followed by DC cardio version. The patient was stabilized and declared fit to go for hemorrhoid surgery after 3 months.

**VIGO ECG played a crucial role in the diagnosis and management of his condition.**



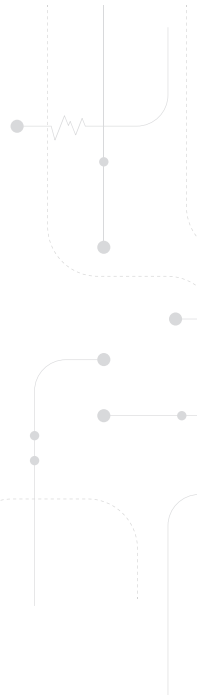
# NON-SUSTAINED VENTRICULAR TACHYCARDIA



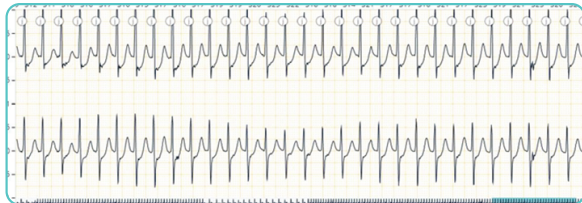
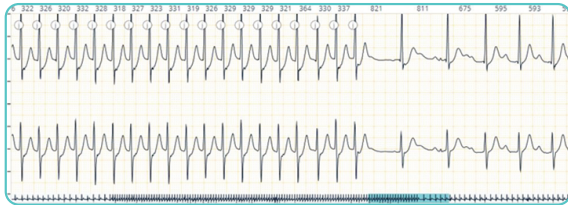
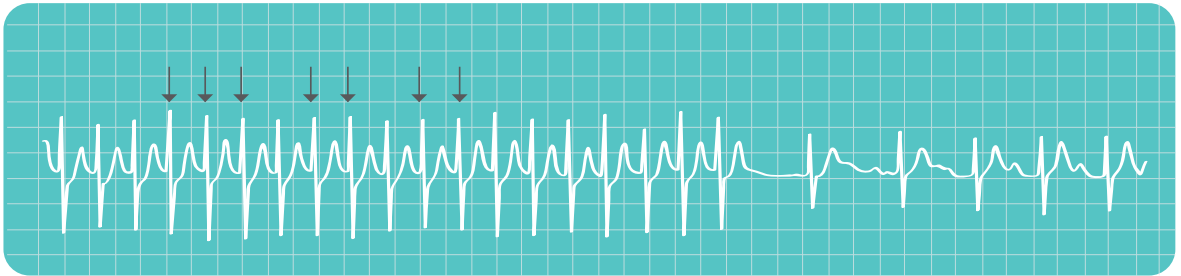
## CASE ANALYSIS 11

### NON-SUSTAINED VENTRICULAR TACHYCARDIA

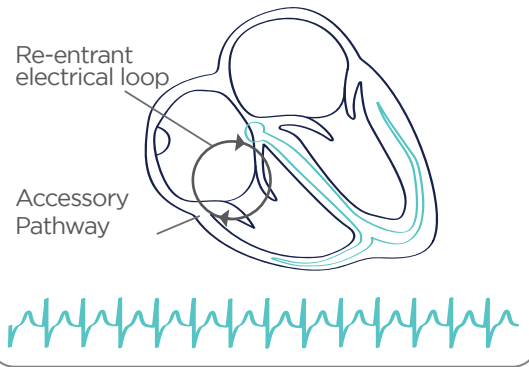
A 72-year-old male patient presented in the OPD with chief complaints of shortness of breath and palpitations. Laboratory evaluation showed that his blood parameters were within normal limits. ECG showed frequent PVCs and dilated cardiomyopathy was reported in ECHO. He was put on Vigo SmartHeart long-term ECG monitoring, which showed 3802 non-sustained tachycardia episodes in 24 hours. This diagnosis allowed further management of the VT and he was scheduled for ICD. **SmartHeart made accurate diagnosis and intervention seamless in this case.**



# SUPRAVENTRICULAR TACHYCARDIA



## Supraventricular Tachycardia



## CASE ANALYSIS 12

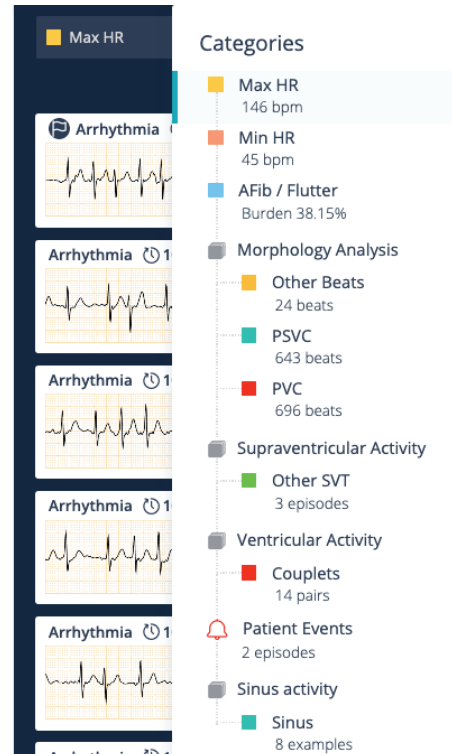
### SUPRAVENTRICULAR TACHYCARDIA

A 76-year-old male with hypertension and diabetes, presented with complaints of rapid palpitations. During his detailed evaluation, the biochemical parameters were within normal limits. Initial ECG and echocardiogram were normal. Long-term ECG monitoring with Smart Heart Showed Supraventricular Tachycardia episodes at 180 beats per minute. The patient was treated in the emergency room due to recurrence of palpitations and received adenosine. Timely diagnosis and intervention is critical for patient's quality of life and safety. In this case, definitive treatment with radiofrequency ablation could be offered because of timely diagnosis.



## REPORT FEATURES

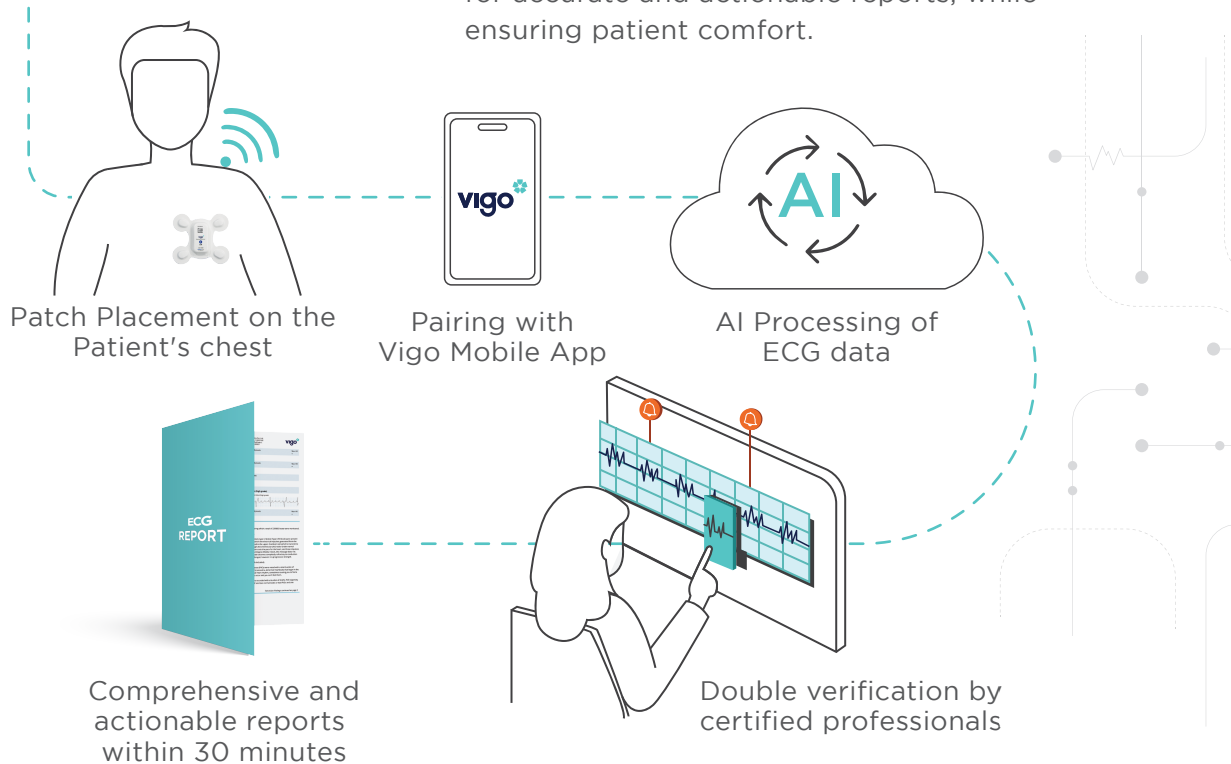
- Our FDA-approved AI is capable of detecting 20+ types of significant events with 96.7% clinical accuracy
- Reports are comprehensive and easy to read
- It records the PVC and PSVC hourly burden
- Heart rate trends are shown in an hourly table
- It also shows results of ventricular morphology analysis and QT analysis
- It is capable of conducting patient event co-relations
- Lorenz plot






## HOW IT WORKS

Revolutionizing arrhythmia detection with biosensors and AI-assisted electrocardiography for accurate and actionable reports, while ensuring patient comfort.





## TOUCH MORE LIVES WITH VIGO SMARtheART

VIGO SmartHeart is easy to recommend, with no upfront capital costs. Use advanced technologies to monitor patients remotely and get accurate diagnoses with the power of Vigo.



+91 95398 95398 | [www.vigocare.com](http://www.vigocare.com)